

Fundoscopic examination

Fundoscopic Examination



- Window to the blood vessels
- Prerequisites-
 - Good ophthalmoscope
 - A large pupil
 - A still field

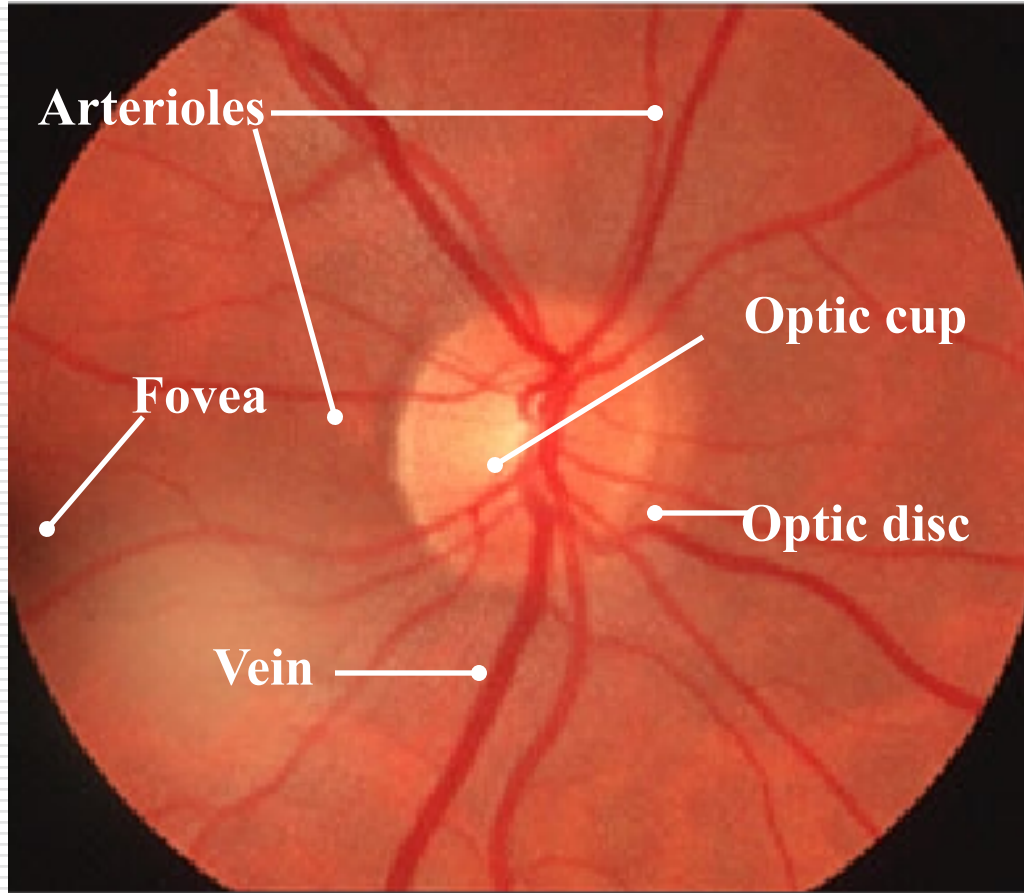
Fundoscopic Examination

- ❑ Diminish illumination in the room(to overcome light reflex)
 - ❑ Instruct the pt to look at a distant point, which is clearly defined(to overcome accommodation and keeping the eye still)
 - ❑ Rt eye for examining rt fundus, Lt eye for left fundus
-

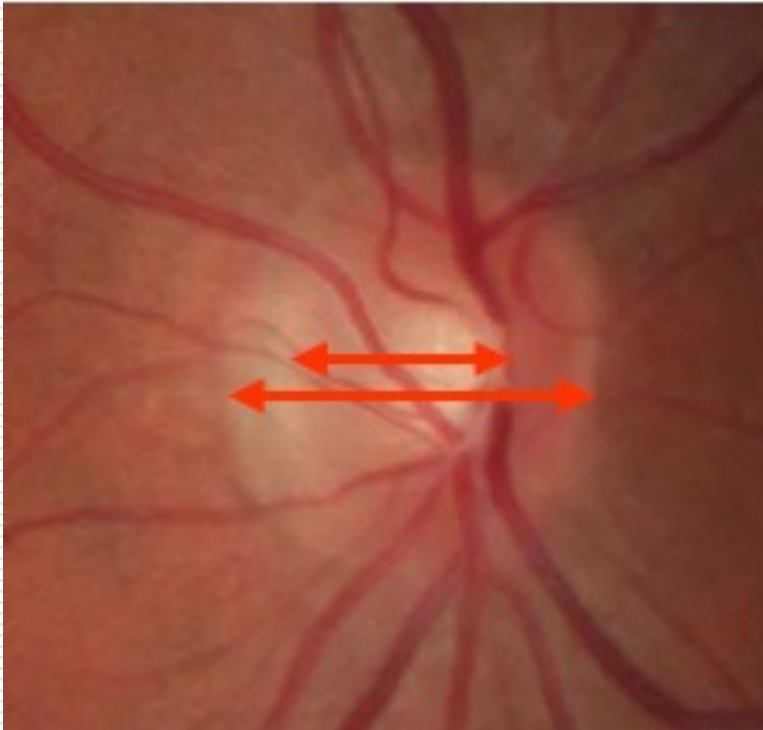
Fundoscopic Examination

- First find the optic disc
 - Colour
 - Edges
 - Optic cup
 - Nasal blurring, temporal pallor- Normal
 - Vessels
 - CRA- superior and inferior branches, nasal & temporal br-four prominent arterial trunks emanating from the disc
 - Vns are larger and darker
 - Arteries are lighter and narrower than vns and often have a central reflecting line – ‘silver-wire’ appearance
 - Point of crossing of arteries and vns
 - Haemorrhage and exudates
 - Macula, Peripheral retina
-

Normal Ocular Fundus



Fundoscopy Examination

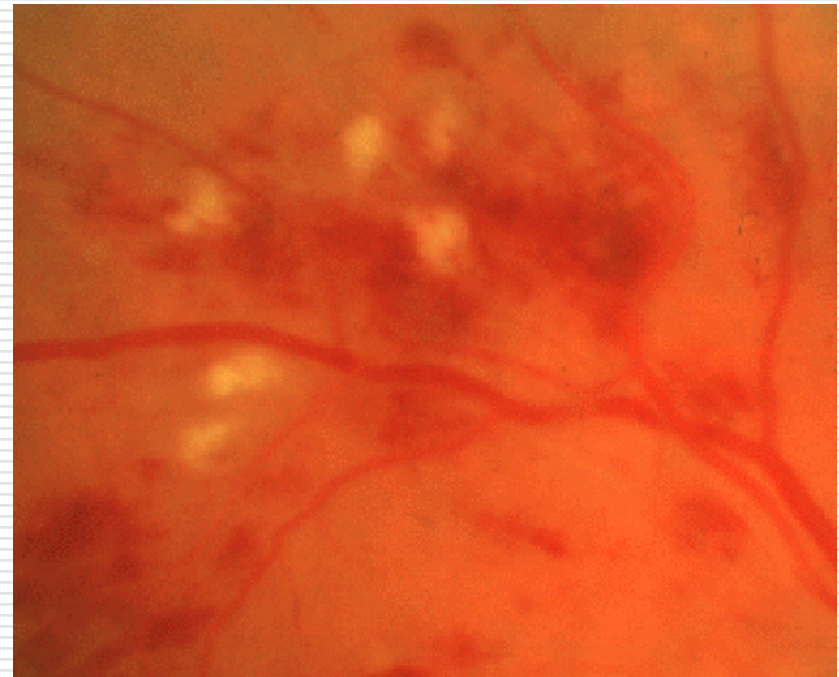


C/D = 0.6

- Cup to Disk Ratio
 - Diameter of the cupped region of the optic nerve head divided by the diameter of the optic nerve head.
- Normal is $\sim 0.3-0.5$.
- Abnormal values are higher and are associated with glaucoma

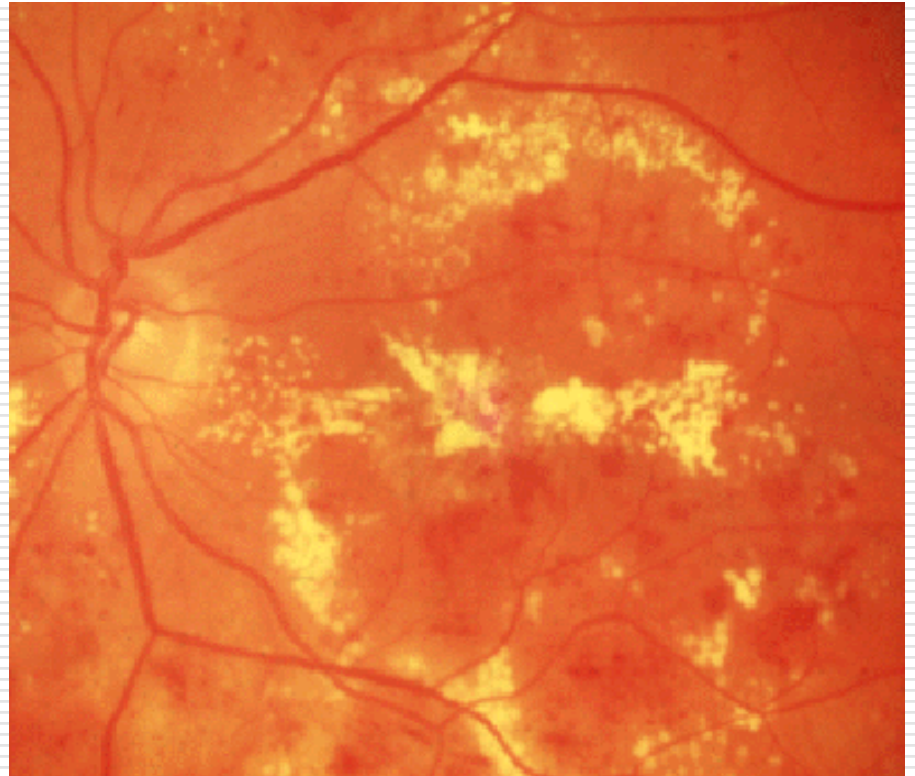
Cotton Wool Spots

- Cotton wool spots result from occlusion of retinal pre-capillary arterioles supplying the nerve fibre layer with concomitant swelling of local nerve fibre axons. Also called "**soft exudates**" or "nerve fibre layer infarctions" they are white, fluffy lesions in the nerve fibre layer.
- Papilloedema, HTN, PAN, retinal embolism, severe anaemia



Hard exudates

- Hard exudates (Intra-retinal lipid exudates) are yellow deposits of lipid and protein within the retina. Accumulations of lipids leak from surrounding capillaries and microaneurysms, they may form a circinate pattern.
- Hyperlipidemia may correlate with the development of hard exudates.



Papilledema- Definition

- Swelling of optic disc
 - Arbitrarily, the term has been reserved for the passive disc swelling associated with raised ICP
 - Usually bilateral, although it may be asymmetrical
-

Causes of papilledema (Raised ICP)

Primary causes

Idiopathic pseudotumor cerebri syndrome (idiopathic intracranial hypertension) with papilledema or without papilledema

Secondary causes

Hydrocephalus

Shunt failure in patient with hydrocephalus (ventriculomegaly may be absent)

Mass lesions—tumor, hemorrhage, large infarction, abscess

Meningitis/encephalitis

Subarachnoid hemorrhage

Trauma

Arteriovenous malformations with high blood flow overloading venous return

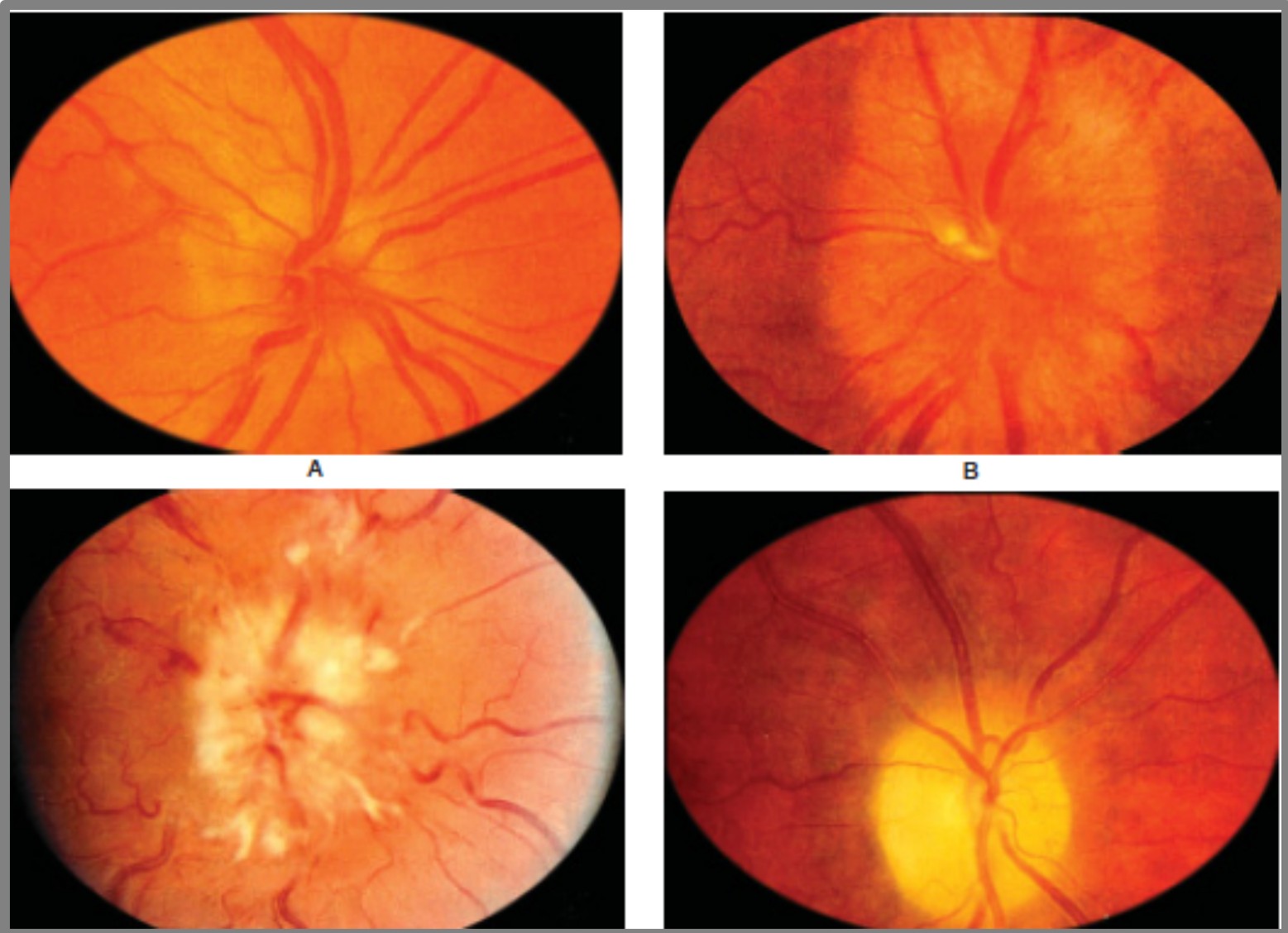
Intracranial or extracranial venous obstruction

Secondary pseudotumor cerebri syndrome due to certain systemic diseases, drugs, or pregnancy

Clinical Features of Papilledema

- Usually bilateral but may be unilateral or asymmetric
 - Usually preserved visual acuity and color vision early
 - May have transient visual loss lasting seconds (obscurations of vision)
 - Visual field defects
 - Enlarged blind spot
 - Generalized constriction
 - Glaucomatous-like defects
 - Eventual peripheral constriction, especially nasally
 - No afferent pupillary defect
-

Papilledema showing blurred disc margins and dilated tortuous vessels



Early papilledema

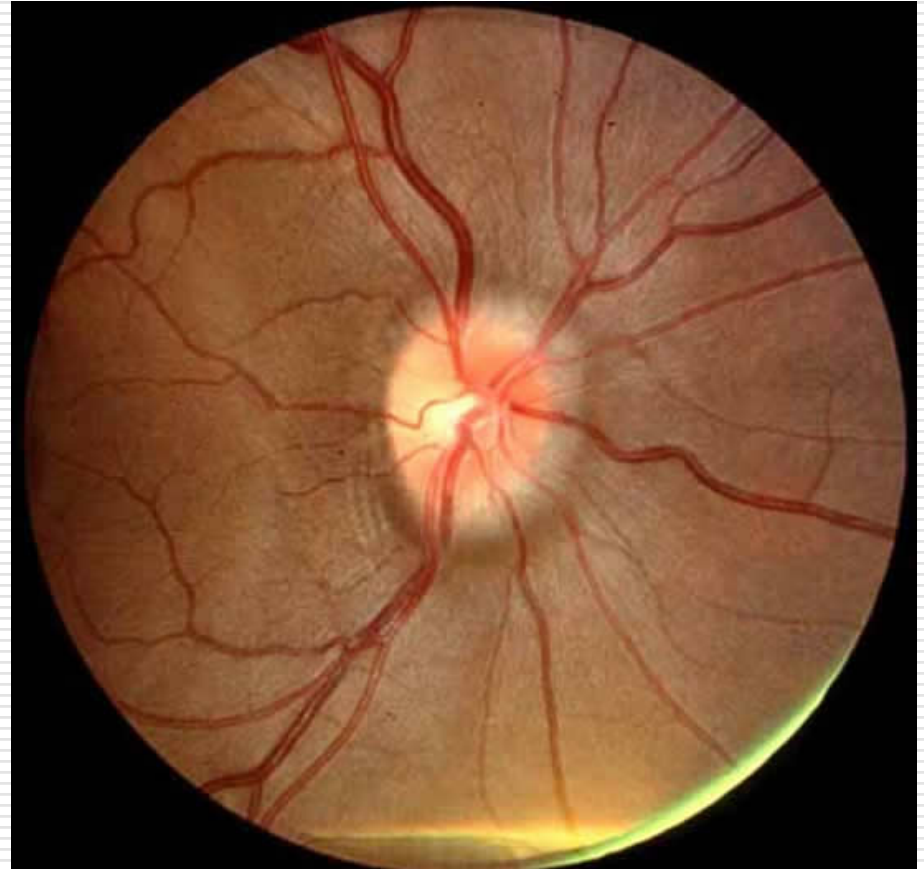
- Minimal disc hyperemia with capillary dilation
 - Early opacification of nerve fiber layer (peripapillary retina loses its superficial linear and curvilinear light reflex and appears red without luster)
 - Early swelling of disc
 - Absence of venous pulsations
 - Peripapillary retinal nerve fiber layer hemorrhage
-

Fully developed papilledema

- Engorged and tortuous retinal veins
 - May have splinter hemorrhages at or adjacent to the disc margin
 - Disc surface grossly elevated
 - Surface vessels become obscured by now opaque nerve fiber layer
 - May have cotton wool spots
 - Paton's lines (circumferential retinal folds) or choroidal folds
 - Hemorrhage and exudates
 - In acute cases (e.g., subarachnoid hemorrhage), subhyaloid hemorrhages may occur that may break into vitreous (Terson's syndrome)
-

Frisen Papilledema Grading System – Stage 1

- ❑ Obscuration of the nasal border of the disc
- ❑ No elevation of the disc borders
- ❑ Disruption of the normal radial nerve fiber layer (NFL) arrangement with grayish opacity accentuating nerve fiber bundles
- ❑ Normal temporal disc margin
- ❑ Subtle grayish halo with temporal gap

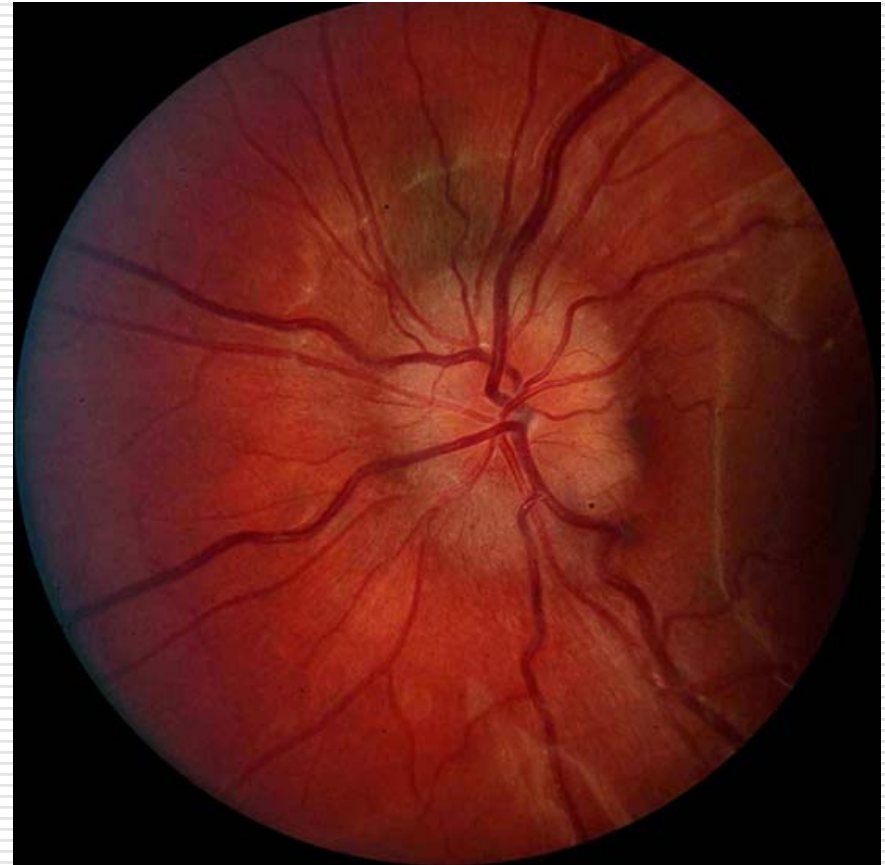


C-shaped halo with a temporal gap

Frisen Papilledema Grading System

– Stage 2

- Obscuration of all borders
- Elevation of nasal border
- Complete peripapillary halo

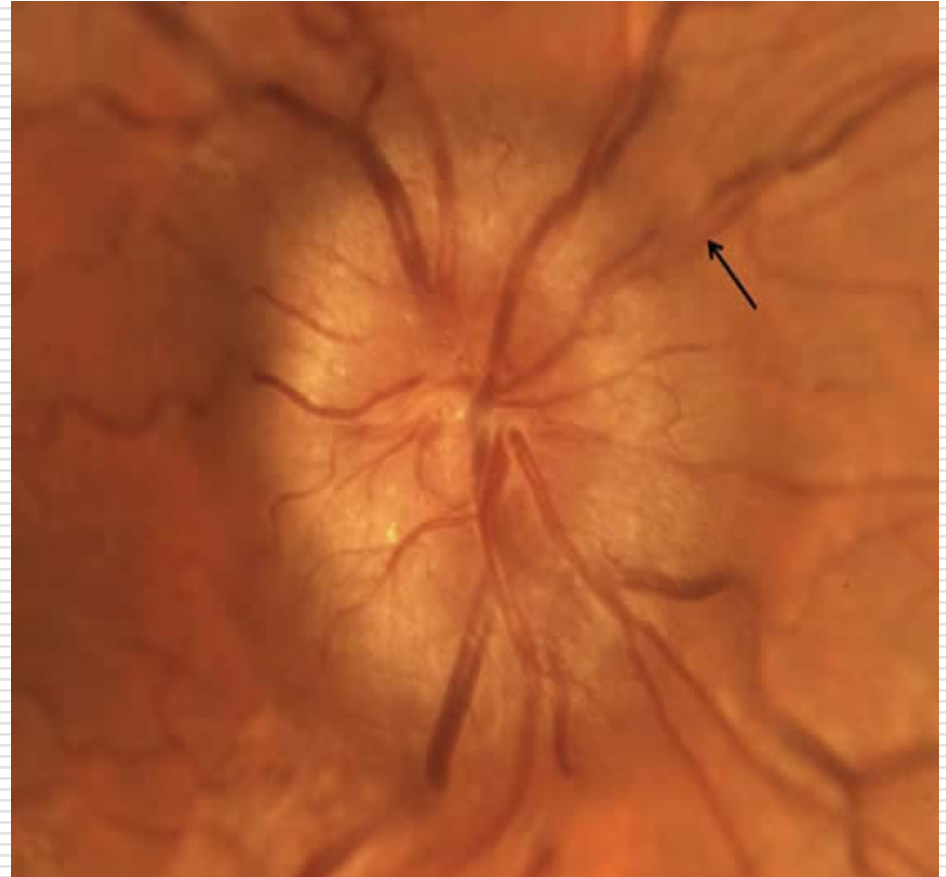

Halo becomes circumferential

Frisen Papilledema Grading System

– Stage 3

- ❑ Obscuration of all borders
- ❑ Elevation of all borders
- ❑ Increased diameter of the optic nerve head
- ❑ Obscuration of one or more segments of major blood vessels leaving the disc
- ❑ Peripapillary halo—irregular outer fringe with finger-like extensions

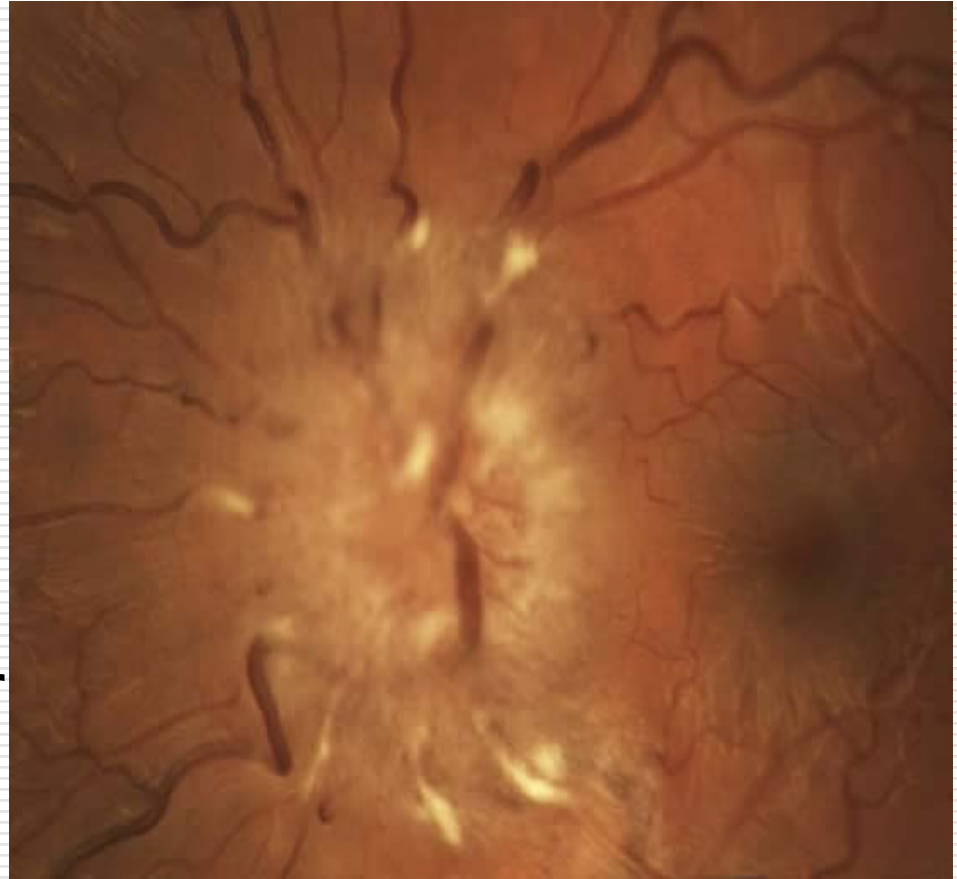

Loss of major vessels as they leave the disc (arrow)

Frisen Papilledema Grading System

– Stage 4

- Elevation of entire nerve head
- Obscuration of all borders
- Peripapillary halo
- Total obscuration on the disc of a segment of a major blood vessel

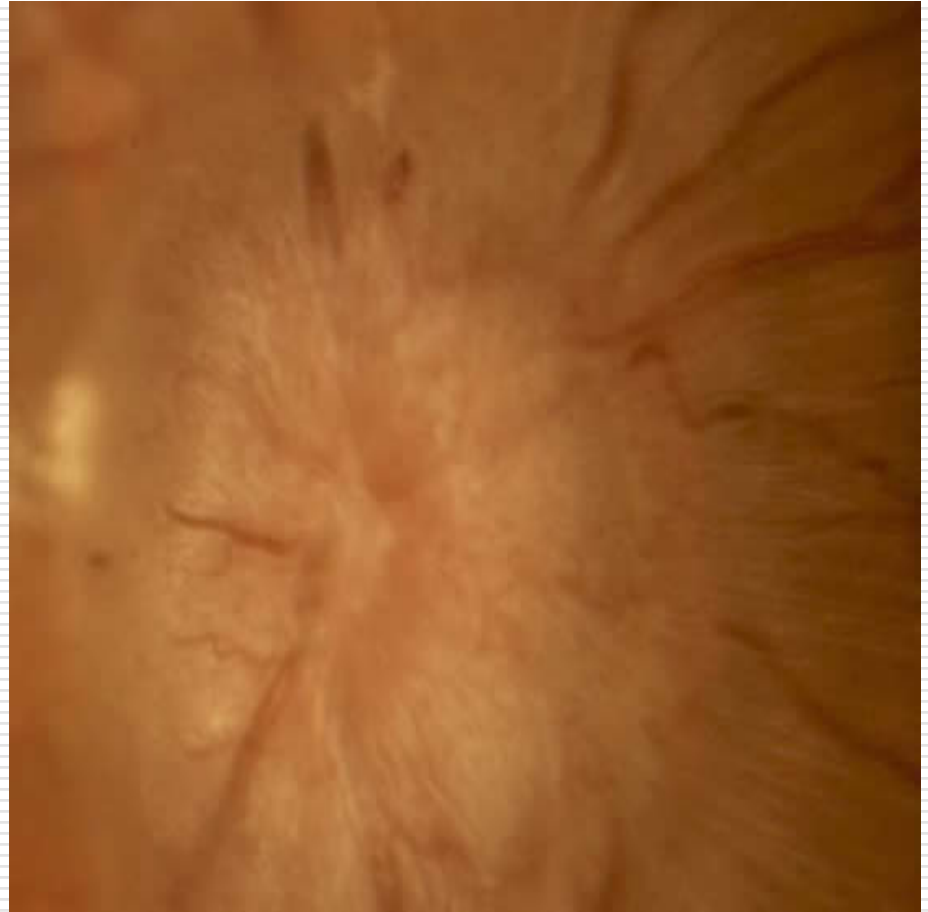

loss of major vessels ON THE DISC

Frisen Papilledema Grading System

– Stage 5

- Dome-shaped protrusions representing anterior expansion of the optic nerve head
- Peripapillary halo is narrow and smoothly demarcated
- Total obscuration of a segment of a major blood vessel may or may not be present
- Obliteration of the optic cup



Grade IV plus partial or total obscuration of all vessels of the disc

Pseudopapilledema

- Optic nerve drusen
 - Medullated nerve fiber
 - Hypermetropic disc
 - Congenital anomalous elevation
-

Optic atrophy - Definition

Optic nerve shrinkage from any process that produce degeneration of axons in the ant.visual (Retinogeniculate) pathway

CLASSIFICATION OF OPTIC ATROPHY

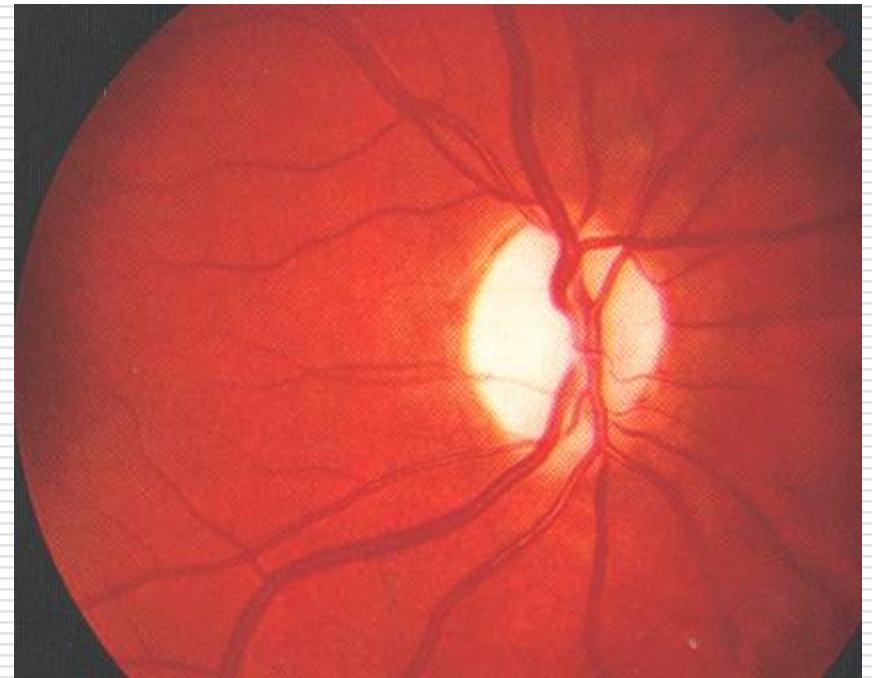
□ PRIMARY-

□ SECONDARY –

- Post- papilloedemic optic atrophy
 - Post-Neuritic optic atrophy
 - Glaucomatous optic atrophy
 - Consecutive optic atrophy
-

PRIMARY OPTIC ATROPHY

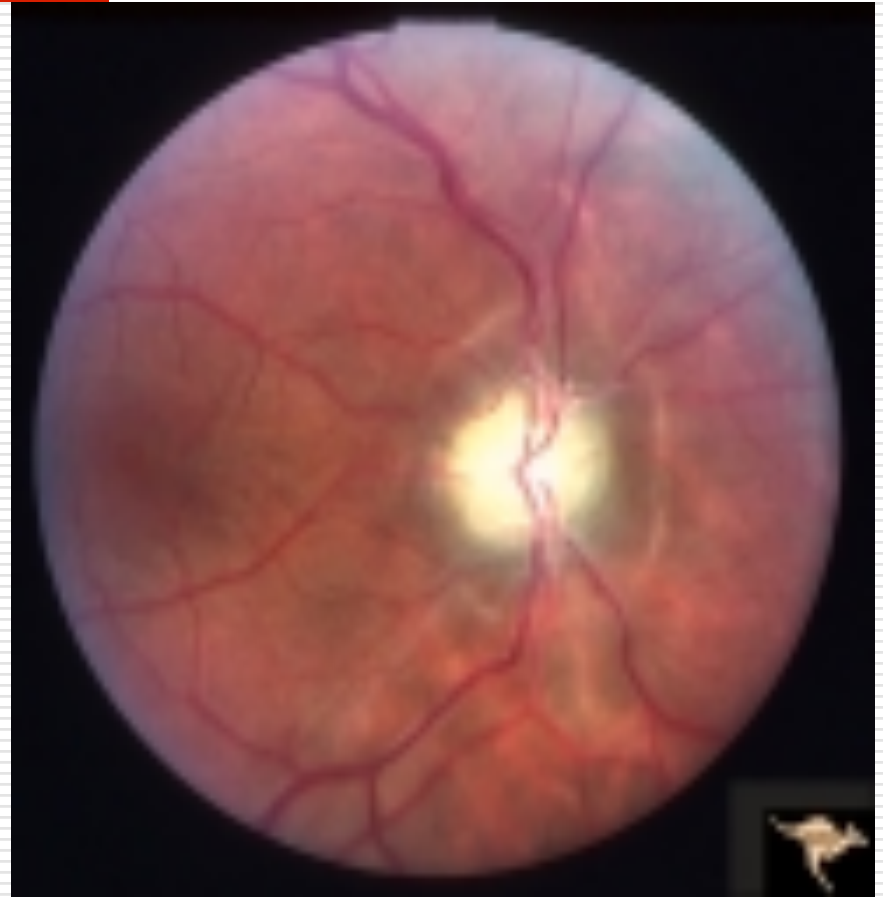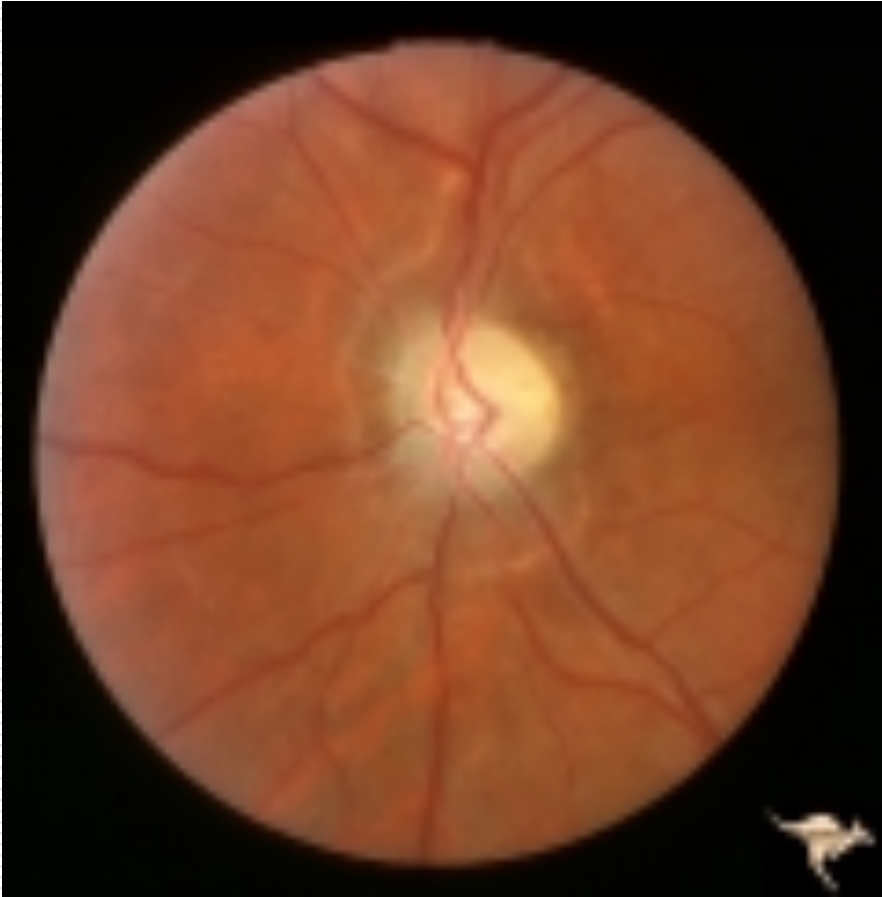- Optic nerve fibers degenerate in an orderly manner and are replaced by columns of glial cells without alteration in the architecture of the optic nerve head
- Pale disc
- Chalky white (full moon against a dark red sky)
- Clear margin of disc/ sharply demarcated
- Normal cup
- Well seen lamina cribrosa
- Normal retinal vessels



Secondary optic atrophy

- Optic nerve fibers exhibit marked degeneration, with excessive proliferation of glial tissue
 - The architecture is lost, resulting in indistinct margins. The disc is grey or dirty grey , looks pale with a greenish tinge
 - The margins are poorly defined,
 - The lamina cribrosa is obscured due to proliferating fibroglial tissue.
 - Hyaline bodies (corpora amylacea) or drusen may be observed.
 - Peripapillary sheathing of arteries as well as tortuous veins may be observed.
-

Secondary optic atrophy



OPTIC ATROPHY

- The Kestenbaum count is the number of capillaries observed on the optic disc.
 - The normal count is approximately 10.
 - In optic atrophy, the number of these capillaries reduces to less than 6; in a hyperemic disc, the count is more than 12
-

Thank You
